

Placental Mesenchymal Dysplasia: A Confusing Entity and the Definitive Role of Histopathology

Maisa H. Mohammed ✉, Nagwa A. Ahmed

Pathology Department, Faculty of Medicine, Sohag University, Sohag, Egypt

Abstract

Background: Placental mesenchymal dysplasia (PMD) is a rare placental disease of poorly understood etiology. It is characterized by aneurysmal dilatation of the chorionic blood vessels, mesenchymal proliferation, and myxomatous degeneration of the stem villi. Although it shares radiological and gross pathological features with partial hydatidiform mole, PMD doesn't necessitate termination of pregnancy.

Case presentation: A 20-year-old woman presented at 25 weeks of gestation with profuse vaginal bleeding and loss of sensation of fetal movements. Abdominal ultrasound revealed a dead fetus and a markedly thick placenta which contains frequent hypoechoic cystic spaces creating a Swiss cheese appearance. Serum β -HCG was within the normal range as regards the gestational stage. A gross examination of the placenta revealed dilated tortuous blood vessels with frequent aneurysms on the placental surface and the cut section showed clotted blood. No definite vesicles were seen. Histopathological evaluation of the placental tissue revealed a mixture of normal and dilated villi with thick chorionic blood vessels and myxomatous degeneration of the villous cores. There was no trophoblastic proliferation, features were kept with PMD.

Conclusion: Placental mesenchymal dysplasia is a rare placental disease that is usually confused with partial hydatidiform mole at both radiological and gross pathological features. However, histopathological examination helps in adopting an accurate diagnosis.

Keywords: Beckwith-Wiedemann Syndrome, Partial hydatidiform mole, Placental mesenchymal dysplasia

Corresponding author: Maisa Hashem Mohammed, MD; Pathology Department, Faculty of Medicine, Sohag University, Egypt; Email: maisahashem@med.sohag.edu.eg

Received: 29-June-2022, **Accepted:** 15-October-2022, **Published online:** 19-October-2022



Introduction

Placental mesenchymal dysplasia (PMD) is a rare clinical entity that was firstly described in 1991 as a mesenchymal hyperplasia of the placental stem villi and aneurysmal dilatation of the chorionic blood vessels ¹. Both of these features lead to large sized placenta and elevation of maternal serum alpha-fetoprotein (AFP). Many previous nomenclatures have been assigned to PMD as placentomegaly with massive hydrops of placental stem villi and pseudo-partial moles ¹. It accounts for 0.02% of all pregnancies ². However, the actual incidence is underestimated because PMD had many previous nomenclatures in the past. Also, PMD is usually a clinically silent disease and is detected only on

routine prenatal sonographic follow-up. It is more common in female fetuses with a female: male ratio of 3.5-4:1 ³.

Placental mesenchymal dysplasia is usually associated with intrauterine fetal death (IUID), intrauterine growth retardation, and many neonatal genetic disorders such as type I diabetes mellitus, unipaternal disomy 6, trisomy 13 and Klinefelter syndrome ⁴. The most important congenital anomaly associated with PMD is Beckwith-Wiedemann syndrome (BWS) which is reported in 23% of cases of PMD. Other literature reported that PMD may co-exist with phenotypically normal infants ¹.

The most important differential diagnosis of PMD is the partial hydatidiform mole (PHM) which is confused with PMD on both sonographic and gross

pathological evaluations. On sonographic evaluation, both PMD and PHM have thick placentas and hypo-echoic placental cystic areas creating a moth-eaten appearance⁵. Partial hydatidiform mole treatment necessitates pregnancy termination and abortive monitoring of β subunit of human chorionic gonadotropin (β -HCG). On the other hand, termination of pregnancy is not performed in PMD⁶.

We report a case of PMD associated with IUFD during the 25th week of gestation.

Case presentation

Patient information and Clinical findings

A 20-year-old pregnant woman presented at 25 weeks of gestation with profuse vaginal bleeding and loss of sensation of fetal movements. The patient was admitted to the Obstetrics and Gynecology Department, Sohag University Hospital. There was no previous history of hypertension, diabetes mellitus, prenatal infectious disease, or trauma. Abdominal ultrasound was performed and it revealed IUFD and a markedly thick placenta which contain frequent hypoechoic cystic spaces creating a Swiss cheese appearance. The possibility of PHM was suspected. However, serum β -HCG was within

the normal range as regards the gestational stage. The post-abortive placenta was sent to the Pathology Laboratory, at Sohag University Hospital. The patient was discharged one day after evacuation and she was generally good.

Pathological features

A gross examination of the placenta revealed dilated tortuous blood vessels with frequent aneurysms on the placental surface. The cut section of the placental tissue showed clotted blood. No definite vesicles were seen. Formalin-fixed and paraffin-embedded placental tissue blocks were prepared. Blocks were sectioned at 5 μ m thick tissue sections and they were stained by hematoxylin and eosin stain.

Microscopic examination revealed an admixture of normal and dilated chorionic villi (Figure 1).

The dilated villi were edematous with occasional central cistern formation and peripherally distributed blood vessels. The walls of the chorionic blood vessels showed hyperplastic fibro-muscular proliferation (Figure 2). Many villi had myxomatous stroma.

All the examined villi were surrounded by a single layer of trophoblastic cells with no proliferation/ inclusions (Figure 3).

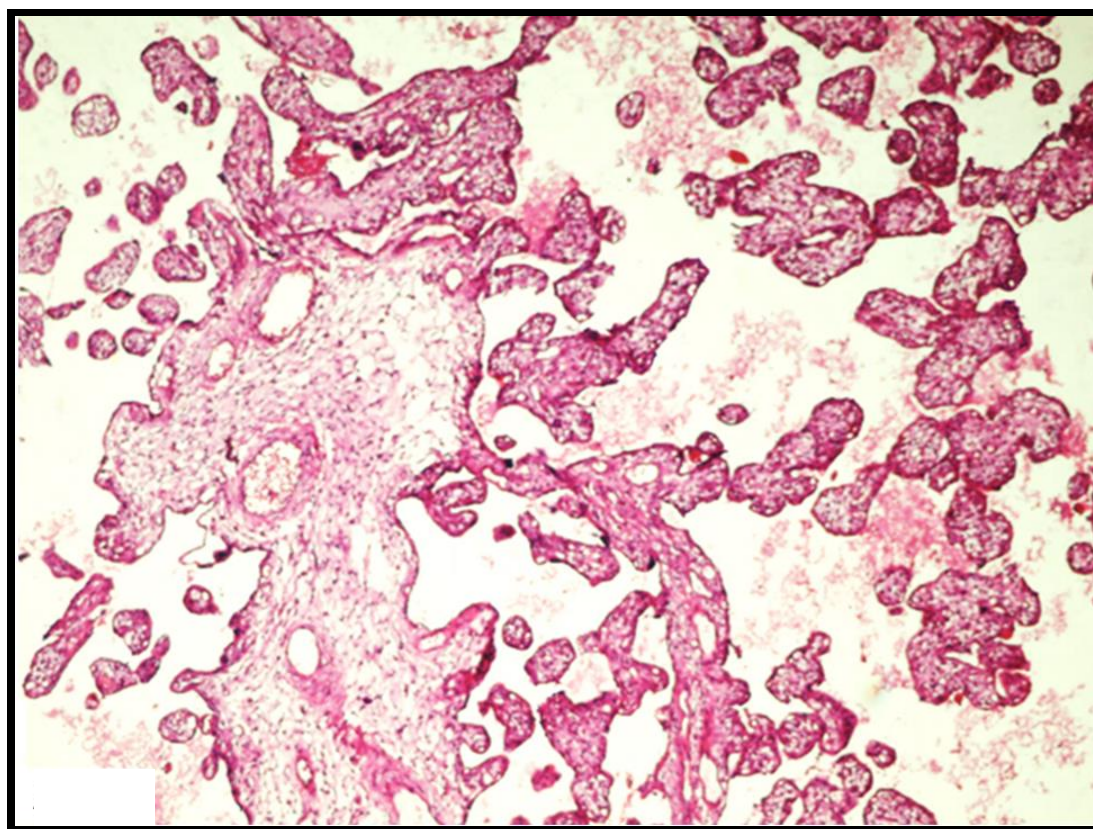


Figure 1: Placental mesenchymal dysplasia showing a mixture of normal (right side) and dilated (left side) chorionic villi (X 100)

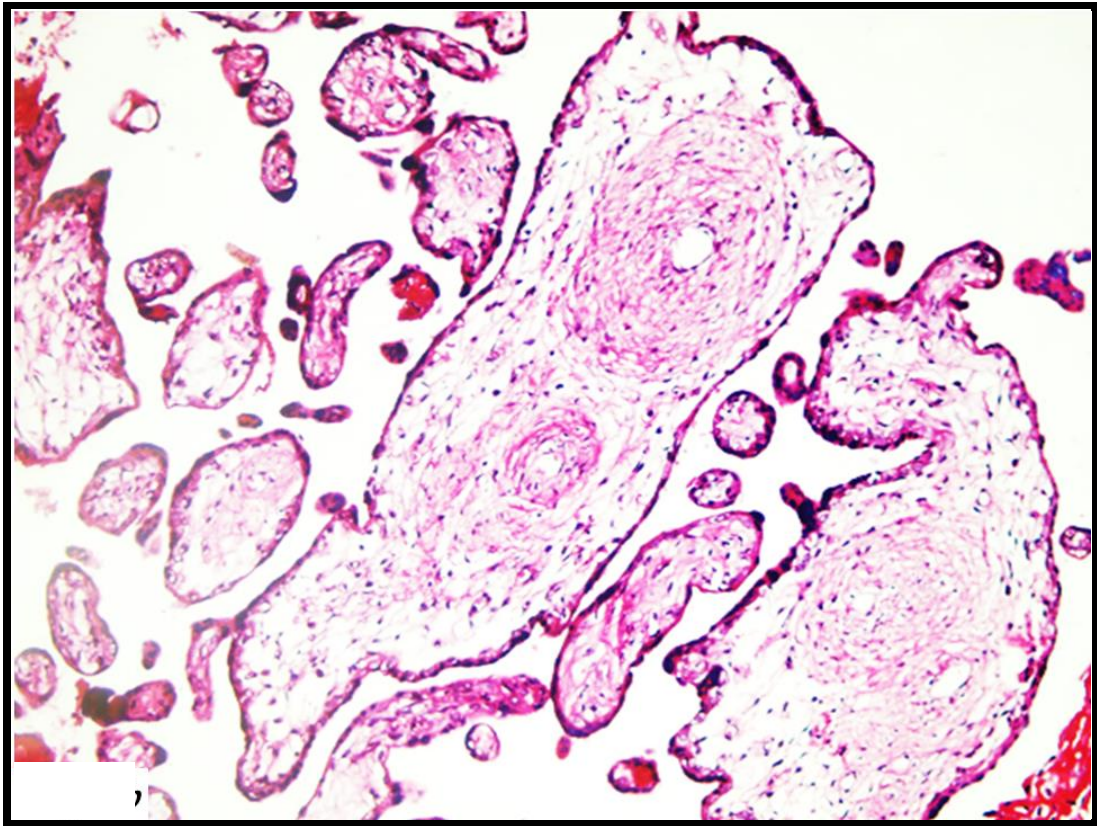


Figure 2: Chorionic blood vessels with hyperplastic muscular walls (X 200)

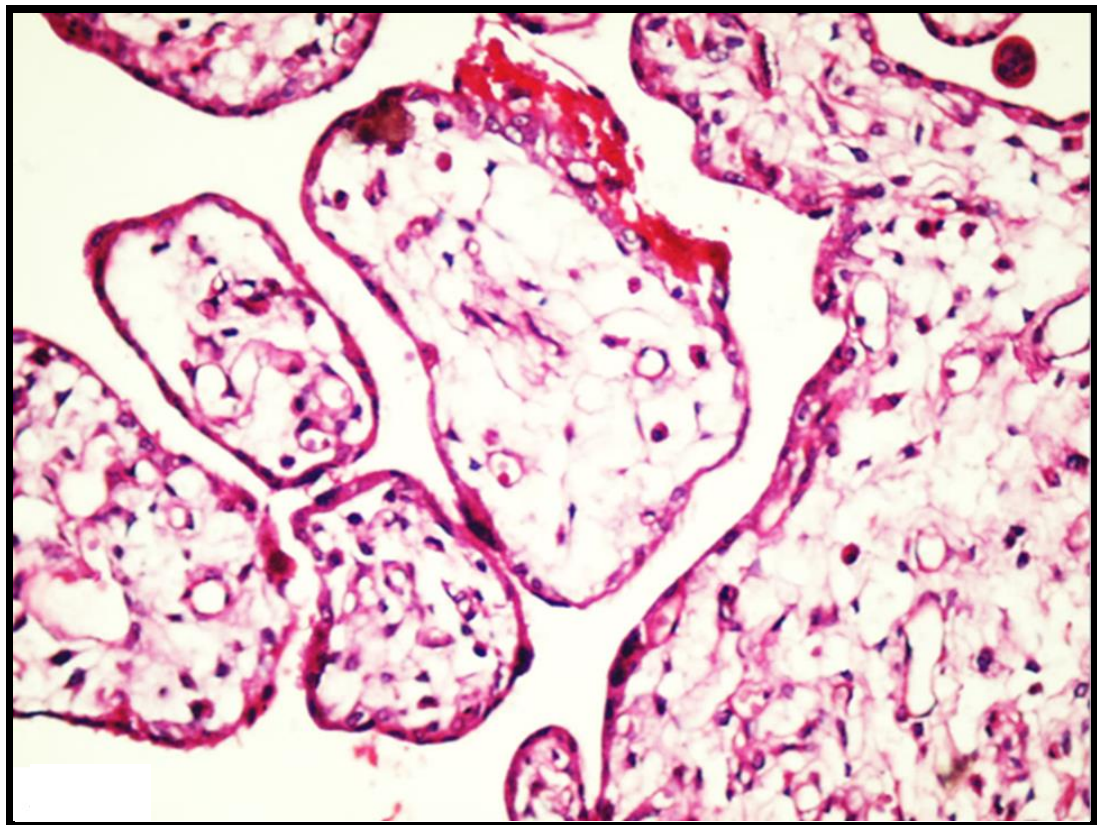


Figure 3: Chorionic villi with no trophoblastic proliferation or trophoblastic inclusions (X 200)

Hyperplasia of the mesenchymal tissues, myxomatous degeneration of the stem villi, and absence of trophoblastic proliferation made the diagnosis of PMD the most appropriate.

Discussion

Placental mesenchymal dysplasia is a rare placental disease in which chorionic vascular abnormalities constitute the hallmarks of that condition. On radiological and gross pathological evaluations, PMD is characterized by placentomegaly and placental cystic spaces, these features are similar to those present in PHM which is the most confusing entity with PMD ⁷. The incidence of PMD is about 0.02% of all pregnancies ². However, due to the innocent course of the disease, the actual incidence of PMD is underestimated ⁵. Many congenital anomalies are associated with PMD, the most frequent congenital anomaly is BWS. It has been estimated that 23% of cases of PMD are associated with BWS in which the fetus has macrosomia, macroglossia, omphalocele, and high incidence of embryonic tumors such as Wilm's tumor and neuroblastomas ⁸. Other congenital anomalies that occur in association with PMD are type I diabetes mellitus, unipaternal disomy 6, trisomy 13, and Klinefelter syndrome ⁴.

Placental mesenchymal dysplasia is characterized by the presence of dilated chorionic blood vessels which may be complicated by thrombosis, rupture, or hemorrhage. These vascular lesions attribute to intrauterine growth retardation and IUID which frequently occur in association with PMD ⁹.

Ohira et al. reviewed 49 articles including 110 cases of PMD. Analysis of the data obtained from the previous literature revealed that about three-fourths of cases of PMD was diagnosed in the 2nd trimester. They also detected that dilatation of the fetal chorionic vessels becomes manifest in the 3rd trimester in most of the reported cases ¹⁰. We supposed that the dominant vesicular changes of the placenta may be responsible for the misdiagnosis of PMD as PHM.

The placental vascular dilatation, especially at the fetal aspect of the placenta, which becomes more dominant in the 3rd trimester may be responsible for the sudden intrauterine fetal death which is frequently observed in this gestational period, especially if the fetus didn't show gross anomalies. Previous studies reported two cases of PMD which

were ended after 31 weeks of gestation, due to sudden IUID. One of these studies detected markedly dilated chorionic vessels at the 28th week of gestation and these vessels ruptured in the 31st week followed by IUID ^{2,11}.

The etiology of PMD is not fully understood and several theories were adopted. The first theory postulated that PMD is a congenital malformation of the mesoderm. This theory was strongly supported by the microscopic features of PMD as there is mesenchymal hyperplasia in the stem villi, myxomatous degeneration in the villous stroma, and thick fibro-muscular walls of the chorionic vessels. Other evidence which supports this theory is the frequent association between PMD and BWS which is characterized by overgrowth ³.

The second theory postulated that PMD results from hypoxic conditions which occur during pregnancy due to undetermined causes. Hypoxia stimulates the production of hypoxia-inducible factors which in turn stimulate the production of vascular endothelial growth factor and angiogenesis. Hypoxia also stimulates fibroblasts to produce connective tissue fibers ¹².

The main differential diagnosis of PMD is PHM. However, there are some differences in the clinical, sonographic, and pathological aspects. Clinically, PMD is usually a silent condition that is suspected only on routine prenatal sonographic evaluation, serum β -HCG is normal or slightly elevated in PMD and returns rapidly to normal level after the end of pregnancy because there is no trophoblastic proliferation. Serum maternal AFP is elevated. Authors explained the elevation of serum maternal AFP as the placental surface area is increased and accompanied by dilated blood vessels. So, excess AFP is passed from the fetal to maternal circulation ⁷.

On sonographic evaluation, the hypoechoic cystic spaces in PMD are migratory. They are initially located deep in the placental parenchyma in early pregnancy then they move toward the chorionic plates as the pregnancy advances. So, routine prenatal sonographic follow-up helps in suspecting PMD. These cystic spaces represent aneurysmal dilatations of both placental veins and arteries ¹. Another sonographic finding of PMD is the presence of large-sized and cystic placenta accompanied by phenotypically normal fetus ¹³. Histopathologically, PMD shows conclusive features, there is a combination of normal and dilated villi, and the latter have edematous cores and peripherally-located, thick-walled blood vessels. Frequent

myxomatous degeneration of the villi is present. No trophoblastic proliferation, intra-villous trophoblastic inclusions, or peripheral scalloping can be seen with thorough histological examination¹⁴.

In conclusion, PMD is a rare placental disease with radiological and gross pathological features similar to PHM. Discrimination between these two placental diseases by sonographic and histopathological assessment is mandatory to avoid unnecessary termination of pregnancy and extensive treatment and to detect the actual incidence of PMD.

Acknowledgments

Not applicable

Authors' contribution

Conception or design: Both authors; Acquisition, analysis, or interpretation of data: MHM; Drafting the manuscript: MHM; Revising the manuscript: NAA; Approval of the manuscript version to be published: Both authors; Agreement to be accountable for all aspects of the work: Both authors.

Conflict of interest

The authors declare that they have no conflict of interest to disclose.

Data availability

Included in the manuscript.

Ethical considerations

This case report was approved in January 2022 by the Ethics Committee of Sohag Faculty of Medicine, Sohag, Egypt. Verbal consent was obtained from the patient as she was discharged from the hospital one day after uterine evacuation.

Funding

Not applicable.

Study registration

Not applicable.

References

1. Moscoso G, Jauniaux E, Hustin J. Placental vascular anomaly with diffuse mesenchymal stem villous hyperplasia. A new clinico-pathological entity? *Pathol Res Pract*. 1991; 187(2-3): 324-328.
2. Sudano MC, D'Emidio L, Mangiafico L, Mobili L, Giorlandino C. Placental mesenchymal dysplasia, a case of intrauterine sudden death in a normal-sized fetus. *J Prenat Med*. 2013; 7(1): 9-11.
3. Parveen Z, Tongson-Ignacio JE, Fraser CR, Killeen JL, Thompson KS. Placental mesenchymal dysplasia. *Arch Pathol Lab Med*. 2007; 131(1): 131-137.
4. Johnson SL, Walters-Sen LC, Stanek JW. Placental Pathology in Placental Mesenchymal Dysplasia with 13q12.11 Deletion and a 25-Week Gestation Female Infant. *Am J Case Rep*. 2018; 19: 369-373.
5. Pawoo N, Heller DS. Placental mesenchymal dysplasia. *Arch Pathol Lab Med*. 2014; 138(9): 1247-1249.
6. Ning F, Hou H, Morse AN, Lash GE. Understanding and management of gestational trophoblastic disease. *F1000Res*. 2019; 8: F1000 Faculty Rev-428.
7. Mehedintu C, Frincu F, Ionescu OM, et al. A Challenging Diagnosis: Placental Mesenchymal Dysplasia-Literature Review and Case Report. *Diagnostics (Basel)*. 2022; 12(2): 293.
8. Weksberg R, Shuman C, Beckwith JB. Beckwith-Wiedemann syndrome. *Eur J Hum Genet*. 2010; 18(1): 8-14.
9. Doroftei B, Neculai-Valeanu S, Simionescu G, et al. A case report of placental mesenchymal dysplasia: A rare case of a genetically normal fetus with severe intrauterine growth restriction. *Medicine (Baltimore)*. 2019; 98(8): e14554.
10. Ohira S, Ookubo N, Tanaka K, et al. Placental mesenchymal dysplasia: chronological observation of placental images during gestation and review of the literature. *Gynecol Obstet Invest*. 2013; 75(4): 217-223.
11. Yamada A, Sakaida N, Okamura A, Yamada T, Ota T, Bo M. Placental mesenchymal dysplasia, a case of intrauterine sudden death. *Kobe J Med Sci*. 2014; 60(1): E1-E4.
12. Kotani T, Sumigama S, Tsuda H, et al. A case report of placental mesenchymal dysplasia with an increased VEGF-D expression. *Placenta*. 2012; 33(10): 888-891.
13. Pal S, Bose K, Ch Mondal P, Chakrabarti S, Sikder M. Placental Mesenchymal Dysplasia with Normal Fetus: A Rare Case Report. *Iran J Pathol*. 2017; 12(3): 307-310.
14. Matsui H, Iitsuka Y, Yamazawa K, et al. Placental mesenchymal dysplasia initially diagnosed as partial mole. *Pathol Int*. 2003; 53(11): 810-813.