

# The Outcome of Patients with Cerebral Arteriovenous Malformations (AVMs) Treated with Stereotactic Radiosurgery (SRS) Using the CyberKnife (Rationale, Benefits and Risks): A Real-World Experience

Ahmed A. Awad <sup>1, 2</sup>, Ameen S. Alomair <sup>1</sup>, Mohammed M. Rizwanullah <sup>1</sup>, Adnan S. Alhebshi <sup>3</sup>, Amr G. Taha <sup>4, 2</sup>, Faisal S. Alzorkany <sup>5</sup>, Mohammed A. Alkafi <sup>5</sup>, Joti Phattacharya <sup>6</sup>, Ahmed M. Elashwah <sup>1, 7</sup> ✉

<sup>1</sup> Section of Radiation Oncology, Oncology Center, King Faisal Specialist Hospital and Research Centre, Riyadh, Saudi Arabia; <sup>2</sup> Radiation Oncology Department, National Cancer Institute, Cairo University, Cairo, Egypt; <sup>3</sup> Radiation Oncology Department, Johns Hopkins Aramco Health Care, Dhahran, Saudi Arabia; <sup>4</sup> Radiation Oncology Department, King Fahad Specialist Hospital, Buraydah, Saudi Arabia; <sup>5</sup> Biomedical Physics Department, King Faisal Specialist Hospital and Research Center, Riyadh, Saudi Arabia; <sup>6</sup> Intervention Radiology Department, King Faisal Specialist Hospital and Research Center, Riyadh, Saudi Arabia; <sup>7</sup> Department of Clinical Oncology and Nuclear Medicine, Kasr Al-Ainy Faculty of Medicine, Cairo University, Cairo, Egypt

## Abstract

**Background:** Cerebral arteriovenous malformations (AVMs) are complex, heterogeneous, uncommon lesions that carry a high risk of intracranial hemorrhage with subsequent disability.

**Aim:** To evaluate the outcome of patients with cerebral AVMs treated in our center, King Faisal Specialized Hospital and Research Center (KFSSH&RC) Saudi Arabia with SRS using the CyberKnife.

**Methods:** Medical records of patients treated in the above-mentioned way in the period between 2009-2021 were retrospectively evaluated.

**Results:** A total of 51 patients were included in this study. The median age at diagnosis was 31 (3-77) years. Neurological alteration and intracranial hemorrhage were the most common presentations in 24 (47.1%) patients. The mean maximum AVM nidus diameter and volume were 2.9 cm and 5.9 cc respectively. All the patients received SRS using CyberKnife with a median marginal dose of 20 (14-21) Gy over a single fraction. Volume staged treatment was applied in 4 (7.8%) patients. After a median follow-up of 37 (2-170) months, all patients were alive with successful obliteration of the AVM nidus occurring in 31 (60.8%) patients after a median latency period of 27 (4-68.9) months in those who achieved complete obliteration. No patients developed post-SRS hemorrhage and 11 (21.6%) patients developed post-SRS radiological radiation-induced changes of which only 3 (27.3%) patients were symptomatic (in the form of uncontrolled seizures). Only SRS dose > 19 Gy was significantly correlated with the obliteration rate, as 79.3% of patients who received SRS dose > 19 Gy achieved obliteration vs 36.4% only in those who received dose <19 Gy, p value 0.002.

**Conclusion:** SRS treatment using CyberKnife is effective management for patients with cerebral AVMs without an increase in the incidence of post-SRS hemorrhage, stroke, or death.

**Keywords:** Arteriovenous malformations, CyberKnife, Stereotactic radiosurgery.

**Corresponding author:** Ahmed M. Elashwah, MD; Section of Radiation Oncology, King Faisal Specialized Hospital and Research Center (KFSHRC), Riyadh, Saudi Arabia; Email: [aelashwah@kfshrc.edu.sa](mailto:aelashwah@kfshrc.edu.sa)

**Received:** 25-December-2023, **Accepted:** 14-February-2024, **Published online:** 30-March-2024



## Introduction

Cerebral arteriovenous malformations (AVMs) are complex, heterogeneous, uncommon lesions that are considered the most dangerous cerebrovascular malformations due to their propensity for causing intracranial hemorrhage, often leading to severe consequences<sup>1,2</sup>.

Arteriovenous malformations are commonly diagnosed as an incidental finding while investigating unrelated symptoms with an annual incidence of 0.1 percent of the population<sup>3</sup>. Ninety percent of cerebral AVMs are found in supratentorial regions, while the remaining 10 percent occur in the posterior fossa<sup>4</sup>.

The pathogenesis behind cerebral AVM is not fully understood. In the beginning, it was considered a sporadic congenital developmental vascular lesion, but this theory has been declined by many well-documented reports<sup>5-7</sup>. Genetic variations may influence brain AVM development and clinical course<sup>8-10</sup>, with the most common genetic cause of brain AVMs being hereditary hemorrhagic telangiectasia (HHT; Osler-Weber-Rendu syndrome), which is an autosomal dominant condition<sup>11</sup>.

Treatment modalities for cerebral AVMs encompass conservative medical management as well as active interventions such as microsurgical excision or stereotactic radiosurgery (SRS). Endovascular embolization is commonly employed as a supplementary intervention, typically in conjunction with surgery and less frequently in conjunction with SRS<sup>12</sup>.

Conservative medical management appears to be the preferred treatment approach for unruptured AVMs, as indicated by two significant prospective analyses: the trial of unruptured brain AVMs (ARUBA)<sup>13</sup> and the Scottish Audit of Intracranial Vascular Malformations (SAIVM) study<sup>14</sup>. Both showed significantly worse outcomes with active intervention (primarily endovascular embolization). Nevertheless, as elaborated upon below, considerable debate persists regarding the optimal management strategy for patients with this condition. For ruptured AVMs, active treatment is required to prevent subsequent

hemorrhage, which occurs at a higher rate after the initial hemorrhage. SRS is highly effective when used to treat small cerebral AVMs < 2.5 cm in diameter. It is usually given in single or multiple fractions (usually less than five) to induce progressive thrombosis of properly selected lesions via fibro intimal hyperplasia and subsequent luminal obliteration<sup>6</sup>.

Two commonly utilized SRS modalities, Gamma Knife and CyberKnife, are extensively employed in treating patients with cerebral AVMs. CyberKnife offers advantages over Gamma Knife, notably in delivering non-isocentric beams with highly conformal dosing via precise beam delivery at submillimeter ranges facilitated by image-guided radiation therapy (IGRT) technologies. Moreover, immobilization in CyberKnife is flexible and frameless compared to a traditional rigid metal headframe used for immobilization in Gamma Knife, which allows more flexibility in planning and treatment delivery compared to Gamma Knife<sup>15</sup>.

This work aimed to evaluate the outcomes of patients with cerebral AVMs treated with SRS using CyberKnife at the King Faisal Specialized Hospital and Research Center – Riyadh.

## Methods

Retrospective review of the medical records of patients with cerebral AVMs who were treated with SRS using the CyberKnife machine at the Oncology Center of the King Faisal Specialized Hospital and Research Centre (KFSH&RC) in Riyadh, Saudi Arabia in the period from 2009 to 2021.

Data retrieved included age, sex, the maximum size of AVM nidus in cm, the maximum volume in cc, associated aneurysm, and deep venous drainage.

The Spetzler-Martin grading system for AVMs (Table 1) incorporates points assigned to various angiographic features, resulting in a score ranging from grade I to grade V, determined by the sum of points across three categories. Initially employed to forecast the morbidity and mortality risk associated with surgical intervention, it has recently found a

common application in predicting outcomes with alternative treatment modalities<sup>16,17</sup>.

Other retrieved data included previous treatment history before SRS, SRS data (dose, number of beams, and maximum point dose), obliteration rate, and post-SRS complications.

**Table 1: The Spetzler-Martin arteriovenous malformation (AVM) grading system**

Factor	Categories
Size of nidus	Small (<3 cm) = 1
	Medium (3–6 cm) = 2
	Large (>6 cm) = 3
Eloquence of adjacent brain*	Non-eloquent = 0
	Eloquent = 1
Venous drainage	Superficial veins only = 0
	Deep veins = 1

\* Eloquence location means sensory, motor visual cortex, hypothalamus or thalamus, internal capsule, brain stem, and cerebellum.

### ***Stereotactic radiosurgery***

All patients underwent immobilization using a frameless mask. General anesthesia (GA) was administered as necessary, particularly for younger patients, following our protocol for pediatric cases, which entails continuous intravenous propofol infusion to ensure adequate sedation without intubation. Further details regarding our sedation protocol were previously published<sup>18</sup>. A computed tomography (CT) scan simulation was conducted with a slice thickness of 2 mm, with the patient in the supine position and the head of the patient immobilized in a neutral neck position using a custom-molded thermoplastic mask (Posifix™). Subsequently, the patient underwent a thin-slice (1 mm slice thickness) MRI brain simulation with intravenous contrast for delineation purposes. CT and MRI scans were imported into the Accuray™ CyberKnife planning system. Delineation of both the gross target volume (GTV) and organs at risk (OARs) was performed by treating physicians. GTV contouring included the nidus, typically aided by cerebral angiogram, Magnetic Resonance Angiography (MRA), and/or Magnetic Resonance Venography (MRV) following discussions with the corresponding neuroradiology consultant. SRS is typically administered in a single fraction using CyberKnife. However, volume-staged treatment has

been implemented in large-volume lesions, where treatment is delivered over 2-3 fractions separated by 3 months. This approach aims to spare normal brain tissues better and enhance efficacy by delivering higher doses than fractionated SRS<sup>19</sup>.

The prescribed dose typically ranges from 14 to 21 Gy delivered in a single fraction, adjusted based on the target's proximity to organs at risk (OARs) and size. During planning, we aimed to achieve over 98% coverage of the target while adhering to OAR tolerance doses, aiming for a conformality index of 1.2, utilizing fewer than 200 beams per fraction, and completing treatment in less than half an hour. We employed 6D skull tracking during treatment. We utilized fixed collimators for complex and small-sized targets, whereas for larger and regularly shaped targets, we employed the Iris™ collimator.

Following SRS treatment, patients typically undergo regular follow-up with annual brain magnetic resonance imaging (MRI) and cerebral angiography until complete obliteration is confirmed. Subsequently, patients are monitored using MRI/MRA or MRV as indicated.

### ***Endpoints***

The primary endpoint for this study is the obliteration rate. Secondary endpoints include the complication rate, encompassing the incidence of post-SRS hemorrhage and radiological changes, further classified into symptomatic or asymptomatic changes.

### ***Statistical analysis***

The normality of the data was tested using the Kolmogorov-Smirnov test. Numerical data were summarized as means and standard deviations (SD) or medians and ranges, while qualitative data were described as frequencies and percentages. Qualitative data was compared using the Chi-square test or Fisher's exact as appropriate. The Mann-Whitney test was used to compare two groups of quantitative data. Time to obliteration was calculated from the date of SRS to the date of obliteration or last follow-up for those patients who did not develop complete obliteration. The latency period was calculated for those who achieved complete obliteration. The Kaplan-Meier technique was employed to analyze time-to-obliteration. Two-sided p-values were utilized, with values < 0.05 considered significant. Data were

analyzed using the IBM SPSS Statistics for Windows, Version 26.0. (Armonk, NY: IBM Corp).

## Results

**Table 2: Characteristics of 51 patients and AVMs**

Characteristic	Description
<b>Age (years)</b>	
Mean $\pm$ SD	31.8 $\pm$ 16
Median (range)	31 (3-72)
<b>Sex</b>	
Female	24 (47.1%)
Male	27 (52.9%)
<b>Presentation *</b>	
Headache	20 (39.2%)
Seizures	14 (27.5%)
Neurological alteration	24 (47.1%)
Intracranial hemorrhage	24 (47.1%)
<b>Ruptured</b>	
No	27(52.9%)
Yes	24 (47.1%)
<b>Location</b>	
Non-eloquent	22 (43.1%)
Eloquent	29 (56.9%)
<b>Associated aneurysm</b>	
No	37 (72.5%)
Yes	14 (27.5%)
<b>Maximum diameter (cm)</b>	
Mean $\pm$ SD	2.9 $\pm$ 1.3
Median (range)	2.6 (1-6)
<b>Volume (cc)</b>	
Mean $\pm$ SD	5.9 $\pm$ 8.3
Median (range)	3.9 (0.27-53)
<b>Deep venous drainage</b>	
No	23 (45.1%)
Yes	28 (54.9%)
<b>Spetzler-Martin grade</b>	
I	4 (7.8%)
II	23 (45.1%)
III	16 (31.4%)
IV	8 (15.7%)
<b>Treatment before SRS</b>	
No	25 (49%)
Yes	26 (51%)
<b>Type of treatment before SRS (n=26) **</b>	
Embolization	22 (84.6%)
Radiation	1 (3.8%)
Surgery	2 (7.7%)
CSF diversion	2 (7.7%)

\* One patient may have more than one presentation; \*\* One AVM was treated by embolization and surgery; SD: Standard deviation; SRS: Stereotactic radiosurgery; CSF: Cerebrospinal fluid

The study comprised 51 patients, with a median age at diagnosis of 31 years (range: 3-77). Detailed patient and lesion characteristics are provided in Table 2.

All patients underwent SRS using CyberKnife, with a median marginal dose of 20 Gy (14-21) delivered over a single fraction. A representative case treated with a marginal dose of 20 Gy is illustrated in Figure 1.

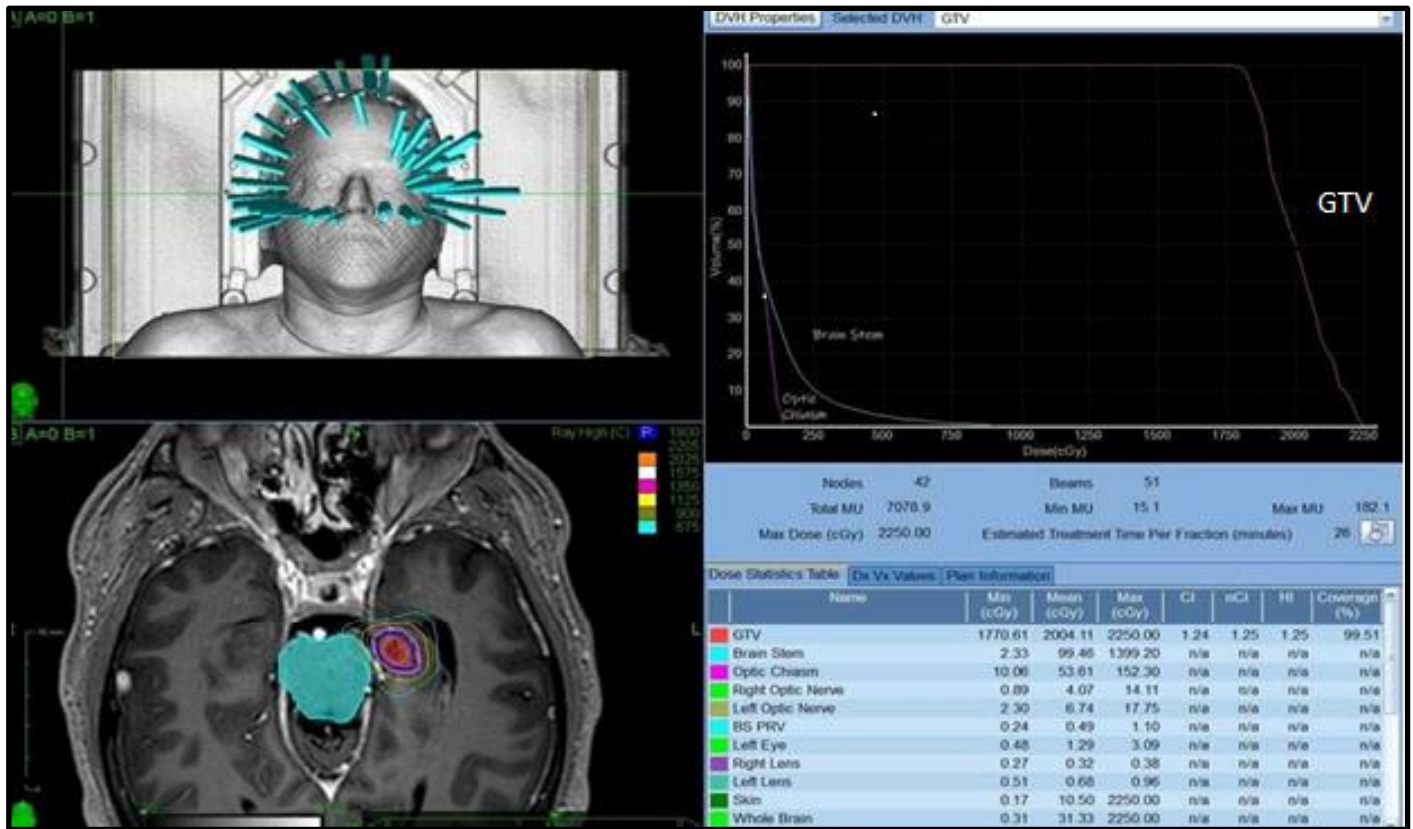
Volume-staged treatment was administered in 4 patients (7.8%). Further details of the SRS treatment are outlined in Table 3.

**Table 3: Stereotactic radiosurgery (SRS), obliteration, and complication details**

	Description
<b>SRS dose (Gy)</b>	
Mean $\pm$ SD	18.8 $\pm$ 1.6
Median (range)	20 (14-21)
<b>Maximum dose %</b>	
Mean $\pm$ SD	125 $\pm$ 1.6
<b>No. of Beams</b>	
Mean $\pm$ SD	160.8 $\pm$ 48.9
Median (range)	160 (47-293)
<b>Successful Obliteration</b>	
No	20 (39.2%)
Yes	31 (60.8%)
<b>Latency period (months)</b>	
Mean $\pm$ SD	30.8 $\pm$ 13.6
Median (range)	27.0 (4-68.9)
<b>Post-SRS radiation changes</b>	
No changes	40 (78.4%)
Asymptomatic changes	8 (15.7%)
Symptomatic changes	3 (5.9%)

Gy: Gray, SD: Standard deviation

With a median follow-up of 37 months (range: 2-170), all patients remained alive, and successful obliteration of the AVM nidus occurred in 31 patients (60.8%). For the whole group the median time to obliteration was 79.8 months (95% CI 32.1- 127.4), with a median latency period of 27 months (range: 4-68.9) in those who achieved complete obliteration. The obliteration rate was higher (68%) in the patients group receiving SRS alone for small-volume disease (< 2.5 cm in diameter) compared to those who received combined SRS and endovascular embolization (50%) for larger-volume disease (> 2.5 cm in diameter).



**Figure 1:** The iso dose covering, beam entry, and dose-volume histogram (DVH) for a case of AVM treated with a dose of 20 Gy in a single fraction

No patients experienced post-SRS hemorrhage, while 11 patients (21.6%) developed post-SRS radiological radiation-induced changes, with only 3 (27.3%) patients exhibiting symptomatic changes in the form of uncontrolled seizures. Regarding the obliteration rate, a statistically significant correlation was found only with SRS doses > 19 Gy, with 79.3% of patients achieving obliteration compared to 36.4% in those receiving doses < 19 Gy (p-value: 0.002), as shown in Table 4.

No significant correlations were found between any factors and the incidence of post-SRS radiological changes in univariate analysis, as indicated in Table 5.

### Discussion

This study presents our experience as a leading center in the Middle East in treating these uncommon lesions in many patients with a robust follow-up period.

**Table 4:** Univariate correlations between factors and the rate of obliteration

Factor	Test statistic	P value
Age	307.5 *	0.961
Sex	0.658 **	0.417
Presentation	0.107 **	0.543
Location	0.632 **	0.427
Associated aneurysm	0.917 **	0.338
Size (cm)	263.5 *	0.369
Volume (cc)	220.5 *	0.09
Deep venous drainage	1.303 **	0.254
Spetzler-Martin grade	1.047 ***	0.849
Treatment history before SRS	1.071 **	0.301
SRS dose	453.5 *	0.002
No. of beams	302.0 *	0.602

\* Mann-Whitney test, \*\* Pearson Chi-square test, \*\*\* Fisher exact test, SRS: Stereotactic radiosurgery

**Table 5: Univariate correlations between factors and the incidence of post-SRS complications**

Factor	Test statistic	P value
Age	142 *	0.074
Sex	0.014 **	0.974
Presentation	0.048 **	0,827
Location	0.031 **	0.861
Associated aneurysm	0.605 **	0.705
Size (cm)	229 *	0.836
Volume (cc)	247 *	0.410
Deep venous drainage	0.432 **	0.511
Spetzler-Martin grade	1.332 ***	0.598
Treatment history before SRS	0.171 **	0.679
SRS dose	228 *	0.839
No. of beams	254.5 *	0.205

\* Mann-Whitney test, \*\* Pearson Chi-square test, \*\*\* Fisher exact test, SRS: Stereotactic radiosurgery

By comparing our data with other studies, we found that the complete obliteration rate of the nidus occurred in 60.8% of our cases, comparable to Starke et al.'s study, where 2236 patients were treated with Gamma Knife radiosurgery, resulting in an overall obliteration rate of 64.7%<sup>20</sup>. This comparable obliteration rate occurred despite the inclusion of larger lesions in our study, as evidenced by the mean maximum AVM diameter and mean volume of 2.9 cm and 5.9 cc, respectively, compared to 2.3 cm and 4.3 cc in the study of Starke et al<sup>20</sup>. Another trial conducted by Kelly et al involved 20 patients treated with CyberKnife radiosurgery and reported a complete obliteration rate of 65%<sup>21</sup>. Once again, we found a comparable complete obliteration rate despite differences in the mean maximum AVM diameter and mean volume, with values of 2.9 cm and 5.9 cc, respectively, in our study compared to 1.8 cm and 4.3 cc in Kelly's study<sup>21</sup>.

The mean SRS dose applied in our patients was 18.3 Gy, compared to 20.5 Gy applied in the Starke et al study<sup>20</sup>. This difference in dose might contribute to the lower obliteration rate in our study compared to that of Starke et al<sup>20</sup>, particularly considering the larger AVM size in our patients. The lesion size may pose a challenge in increasing the SRS dose, as escalating the dose could potentially increase the radiation exposure to surrounding risk structures, leading to heightened acute and late side effects.

The median SRS dose in Kelly et al study<sup>21</sup> was 18 Gy (range: 17.5-19.5 Gy), which is lower than the median dose of 20 Gy (range: 14-21) in our study. Despite this, they achieved a higher obliteration rate. This difference could be attributed to the previously mentioned factors of larger AVM lesion size in our study and a higher proportion of patients with Spetzler grade III (43%) and grade IV (15%) compared to Kelly et al study<sup>21</sup>, where 35% had grade III and only 6% had grade IV lesions.

In this study, SRS dose was the only factor that correlated significantly with the obliteration rate. A high obliteration rate of 79.3% was observed for those who received an SRS dose > 19 Gy, compared to 36.4% for those who received a dose <19 Gy. This finding is consistent with other studies by Starke et al<sup>20</sup> and Kelly et al<sup>21</sup> where the SRS dose was significantly correlated with the obliteration rate.

Our data showed that 22 (43%) patients with large-volume AVMs underwent endovascular embolization before SRS. The rate of complete obliteration in these patients was 50%, which is lower than the obliteration rate of 68% observed in patients with lower-volume AVMs treated with SRS alone. These findings are consistent with previous studies, such as the one by Henkes et al<sup>22</sup>, which included 64 AVM patients treated with embolization and SRS. They concluded that AVM obliteration after embolization and SRS is less frequently achieved than after SRS of primarily small AVMs.

Stereotactic radiosurgery treatment was well-tolerated by our patients, with no reported post-SRS hemorrhage. Additionally, only 21.6% of patients developed post-SRS radiological radiation-induced changes, which is lower than the rates reported by Starke et al<sup>20</sup>, where post-SRS hemorrhage occurred in 7.3% of patients and radiation-induced imaging changes occurred in 29.2%. Similarly, Kelly et al<sup>21</sup> reported that post-SRS hemorrhage occurred in 5% of patients.

One of the primary considerations in SRS treatment for cerebral AVMs is the latency period, which typically takes 2-3 years, sometimes longer, to complete obliteration of the nidus. During this period, patients remain at a heightened risk for intracranial hemorrhage. However, Maruyama et al. found that the risk of hemorrhage after SRS for patients with AVMs decreased by 54% during the latency period and

by 88% after obliteration, compared with the period between diagnosis and SRS <sup>23</sup>.

By comparing the outcomes of our group of patients with unruptured AVMs to those in the ARUBA study (13), we observed that at a median follow-up period of 37 months, the obliteration rate occurred in 55.5% of cases with no reported post-SRS hemorrhage, stroke, or death in any of these patients in our study. This contrasts with a three-fold higher rate of death or symptomatic stroke in patients who underwent intervention compared to those who underwent conservative medical management in the ARUBA study <sup>13</sup>.

These findings suggest a potential shift in managing patients with unruptured AVMs, with more attention given to active intervention. This perspective is supported by another study by Tonetti et al <sup>24</sup>, involving 233 ARUBA-eligible patients with unruptured AVMs treated with SRS instead of conservative medical management. They found that after a mean follow-up of 8.4 years, 72% of patients had successful obliteration with a 13.7% incidence of post-SRS stroke or death, compared to a 13.6% incidence of stroke or death in patients in the conservative medical management arm of the ARUBA trial.

Limitations of our study include its retrospective nature, which is associated with inherent drawbacks. Additionally, the relatively small sample size and relatively short median follow-up time are limitations, particularly in the context of studying benign disorders like cerebral AVMs.

### Conclusion

Stereotactic radiosurgery treatment using CyberKnife is an effective management option for patients with cerebral AVMs, demonstrating efficacy without an increase in the incidence of post-SRS hemorrhage, stroke, or death.

### Acknowledgments

Not applicable.

### Authors' contribution

Conception and design: Awad A, Alomair A & Taha A; Data Collection: Awad A & Elashwah A; Data Analysis and Interpretation: Awad A, Elashwah A & Rizwanullah M; Drafting / Revising the manuscript: Elashwah A, Alomair A, Rizwanullah M, Alhebshi A & Taha A; Approval of the final version of the manuscript: All authors; Agreement to be accountable for all aspects of the work: All authors; Review of images and aiding in the

delineation of nidus: Joti Phattacharya; CyberKnife plan: Faisal Alzorkany & Abdullah Alkafi.

### Conflict of interest

The authors declare that they have no conflict of interest to disclose.

### Data availability

Data is available from the corresponding author upon request.

### Ethical considerations

This research protocol was approved by the Research Advisory Council (RAC) and Research Ethics Committee of the King Faisal Specialist Hospital and Research Centre, Riyadh, Saudi Arabia (RAC Project # 2231426 ).

### Funding

Not applicable.

### Study registration

Not applicable.

## References

1. Brown RD Jr, Wiebers DO, Torner JC, O'Fallon WM. Frequency of intracranial hemorrhage as a presenting symptom and subtype analysis: A population-based study of intracranial vascular malformations in Olmsted county, Minnesota. *J Neurosurg.* 1996; 85(1): 29–32.
2. Ogilvy CS, Stieg PE, Awad I, et al. AHA scientific statement: Recommendations for the management of intracranial arteriovenous malformations: A statement for healthcare professionals from a special writing group of the Stroke Council, American Stroke Association. *Stroke.* 2001; 32(6): 1458-1471.
3. Mohr JP, Kejda-Scharler J, Pile-Spellman J. Diagnosis and treatment of arteriovenous malformations. *Curr Neurol Neurosci Rep.* 2013; 13(2): 324.
4. Willinsky RA, Lasjaunias P, Terbrugge K, Burrows P. Multiple cerebral arteriovenous malformations (AVMs). Review of our experience from 203 patients with cerebral vascular lesions. *Neuroradiology.* 1990; 32(2): 207-210.
5. Dalton A, Dobson G, Prasad M, Mukerji N. De novo intracerebral arteriovenous malformations and a review of the theories of their formation. *Br J Neurosurg.* 2018; 32(3): 305-311.
6. Flemming KD, Lanzino G. Management of unruptured intracranial aneurysms and cerebrovascular malformations. *Continuum (Minneapolis, Minn)* 2017; 23(1, Cerebrovascular Disease):181-210.
7. Pabaney AH, Rammo RA, Tahir RA, Seyfried D. Development of de novo arteriovenous malformation following ischemic stroke: Case report and review of current literature. *World Neurosurg.* 2016; 96: 608.e5-e12.
8. Scimone C, Donato L, Marino S, et al. Vis-à-vis: A focus on genetic features of cerebral cavernous

- malformations and brain arteriovenous malformations pathogenesis. *Neurol Sci.* 2019; 40(2): 243-251.
9. Nikolaev SI, Vetiska S, Bonilla X, et al. Somatic activating KRAS mutations in arteriovenous malformations of the brain. *N Engl J Med.* 2018; 378(3):250-261.
  10. Macmurdo CF, Wooderchak-Donahue W, Bayrak-Toydemir P, et al. RASA1 somatic mutation and variable expressivity in capillary malformation/arteriovenous malformation (CM/AVM) syndrome. *Am J Med Genet A.* 2016; 170(6): 1450-1454.
  11. Bharatha A, Faughnan ME, Kim H, et al. Brain arteriovenous malformation multiplicity predicts the diagnosis of hereditary hemorrhagic telangiectasia: Quantitative assessment. *Stroke.* 2012; 43(1): 72-78.
  12. Barr JC, Ogilvy CS. Selection of treatment modalities or observation of arteriovenous malformations. *Neurosurg Clin N Am.* 2012; 23(1): 63-75.
  13. Mohr JP, Parides MK, Stapf C, et al. Medical management with or without interventional therapy for unruptured brain arteriovenous malformations (ARUBA): A multicentre, non-blinded, randomised trial. *Lancet.* 2014; 383(9917): 614–621.
  14. Al-Shahi R, Bhattacharya JJ, Currie DG, et al. Prospective, population-based detection of intracranial vascular malformations in adults: The Scottish Intracranial Vascular Malformation Study (SIVMS). *Stroke.* 2003; 34(5): 1163-1169.
  15. Chang SD, Main W, Martin DP, Gibbs IC, Heilbrun MP. An analysis of the accuracy of the CyberKnife: a robotic frameless stereotactic radiosurgical system. *Neurosurgery.* 2003; 52(1): 140–146.
  16. Spetzler RF, Martin NA. A proposed grading system for arteriovenous malformations. *J Neurosurg.* 1986; 65(4): 476-483.
  17. Al-Edrus SA, Suhaimi SN, Noor Azman AR, Latif AZ, Sobri M. The Spetzler-Martin grading system and management of patients with intracranial arteriovenous malformation in a tertiary referral hospital. *Malaysian Journal of Medicine and Health Sciences.* 2010; 6(1): 91-99.
  18. Seiler G, De Vol E, Khafaga Y, et al. Evaluation of the safety and efficacy of repeated sedations for the radiotherapy of young children with cancer: A prospective study of 1033 consecutive sedations. *Int J Radiat Oncol Biol Phys.* 2001; 49(3): 771- 783.
  19. Fogh S, Ma L, Gupta N, et al. High-precision volume-staged Gamma Knife surgery and equivalent hypofractionation dose schedules for treating large arteriovenous malformations. *J Neurosurg.* 2012; 117 Suppl: 115–119.
  20. Starke RM, Kano H, Ding D, et al. Stereotactic radiosurgery for cerebral arteriovenous malformations: evaluation of long-term outcomes in a multicenter cohort. *J Neurosurg.* 2017; 126(1): 36–44.
  21. Kelly R, Conte A, Nair MN, et al. Arteriovenous malformations treated with frameless robotic radiosurgery using non-invasive angiography: Long-term outcomes of a single center pilot study. *Front Oncol.* 2020; 10: 570782.
  22. Henkes H, Nahser HC, Berg-Dammer E, Weber W, Lange S, Kuhne D. Endovascular therapy of brain AVMs prior to radiosurgery. *Neurol Res.* 1998; 20(6): 479–492.
  23. Maruyama K, Kawahara N, Shin M, et al. The risk of hemorrhage after radiosurgery for cerebral arteriovenous malformations. *N Engl J Med.* 2005; 352(2): 146-153.
  24. Tonetti DA, Gross BA, Atcheson KM, et al. The benefit of radiosurgery for ARUBA-eligible arteriovenous malformations: a practical analysis over an appropriate follow-up period. *J Neurosurg.* 2018; 128(6): 1850–1854.